

Case Study: Patient Overview

74-year-old Native American woman who presents to the clinic with her daughter for follow up of her diabetes. She has not been seen in over 1 year. During the visit, the patient's daughter reports "My mom's memory has been getting worse over the past year."

Functional Status

Independent with **basic Activities of Daily Living (ADL)**

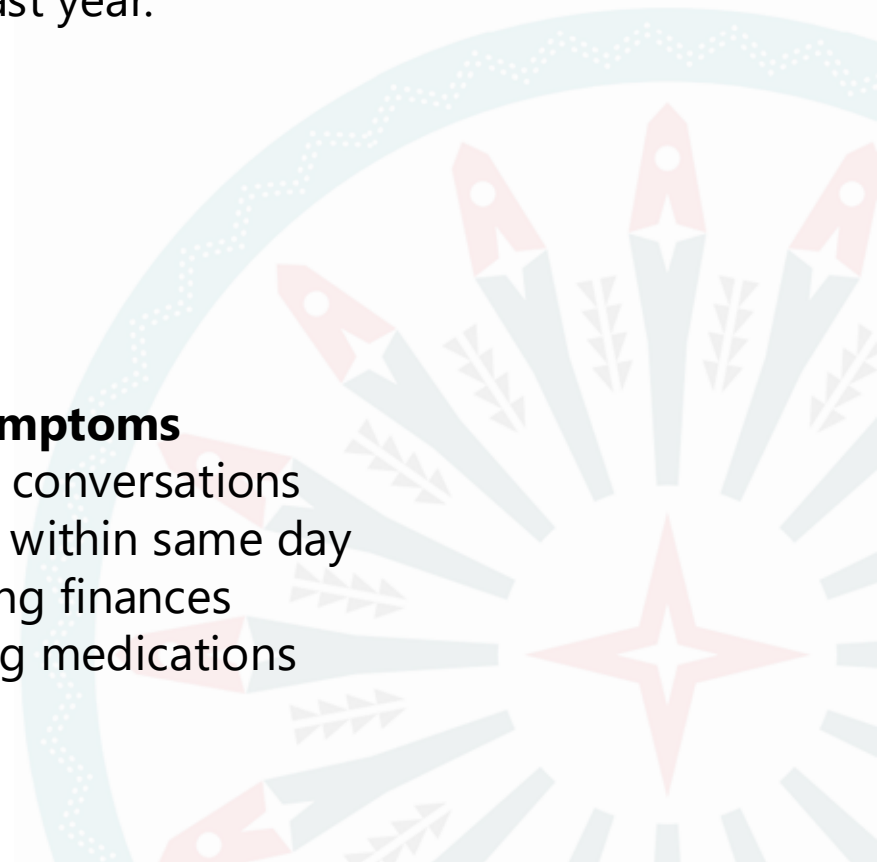
- Bathing
- Dressing
- Feeding

Instrumental ADL difficulty

- Finances
- Medication management

Key Cognitive Symptoms

- Forgetting recent conversations
- Repeating stories within same day
- Difficulty managing finances
- Trouble organizing medications



Case Study: Medical History & Examination

Past Medical History

- Type 2 diabetes (15 yrs)
- Hypertension
- Hyperlipidemia
- Stage 3 CKD
- Diabetic neuropathy
- Osteoarthritis

Medications

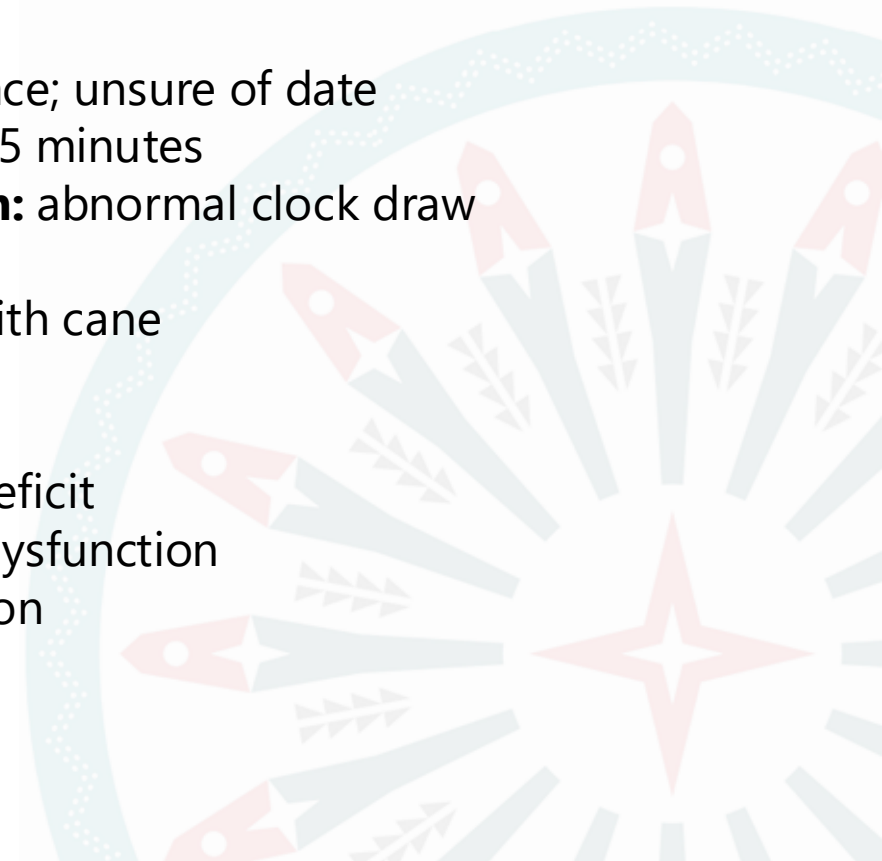
- Metformin
- Lisinopril
- Atorvastatin
- Gabapentin
- Oxybutynin

Neurologic Exam

- Oriented to person/place; unsure of date
- Delayed recall:** 1/5 at 5 minutes
- Executive dysfunction:** abnormal clock draw
- Language intact
- Slow but steady gait with cane

Cognitive Testing

- MoCA: 22/30**
 - Delayed recall deficit
 - Mild executive dysfunction
 - Reduced attention



Case Study: Medical History

Behavior / Mood Changes

- Increased irritability per daughter
- Patient reports **reduced motivation and enjoyment**
- Less involvement in **tribal cultural activities**

Safety Concerns

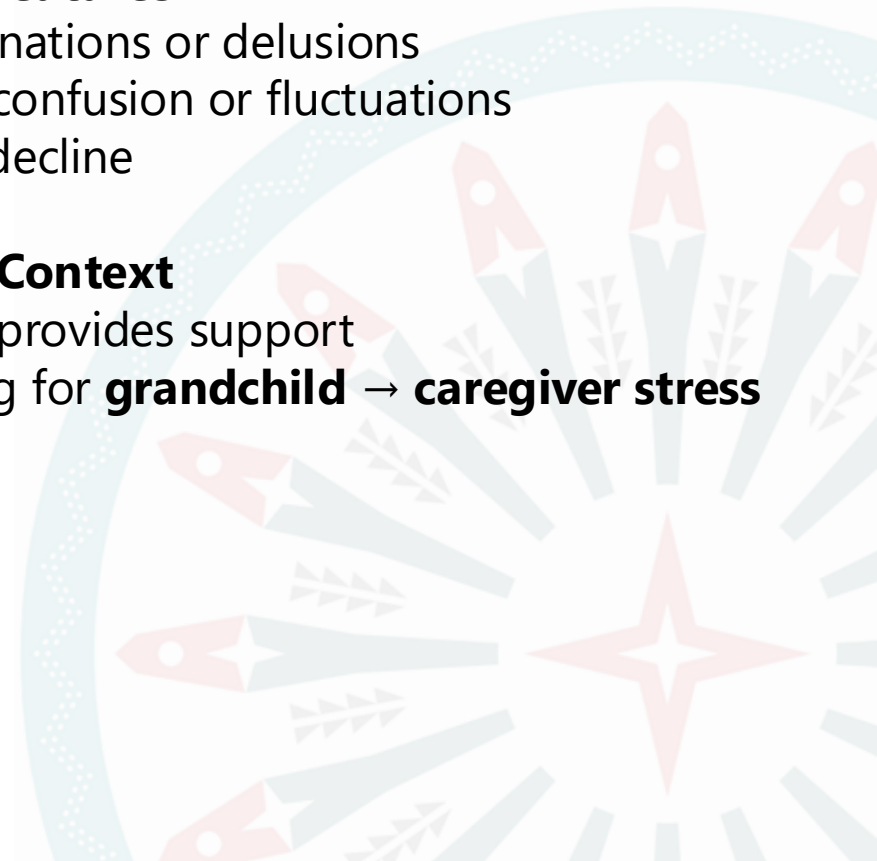
- Got lost once while driving → **stopped driving**
- No wandering
- No stove safety issues

Negative Features

- No hallucinations or delusions
- No acute confusion or fluctuations
- No rapid decline

Caregiver Context

- Daughter provides support
- Also caring for **grandchild** → **caregiver stress**



Questions?



Additional Information

Laboratory Evaluation

- CBC, TSH, B12: Normal
- CMP: Stable CKD
- HbA1c: 9.8%**

MRI Brain

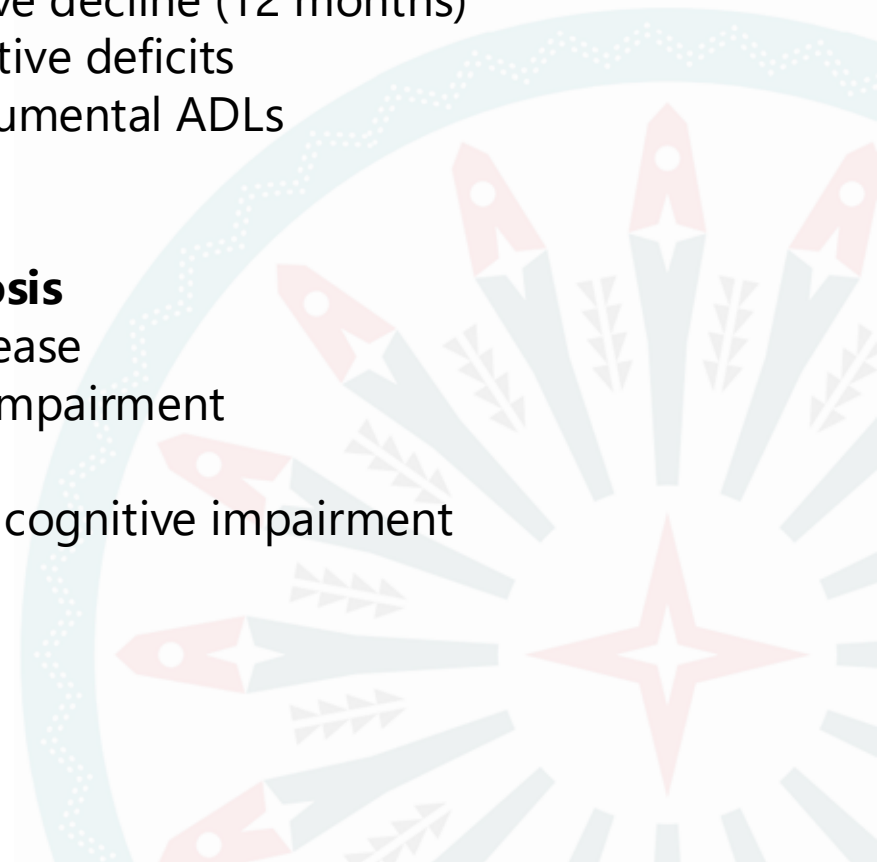
- Mild generalized cortical atrophy
- Mild hippocampal volume loss
- Mild chronic small vessel ischemic changes

Clinical Features

- Progressive cognitive decline (12 months)
- Memory and executive deficits
- Impairment in instrumental ADLs

Differential Diagnosis

- Early Alzheimer disease
- Vascular cognitive impairment
- Mixed dementia
- Depression-related cognitive impairment



Recommendations

